



High species diversity of *Echinococcus* spp. in wild mammals of Namibia

Ortwin Aschenborn^{a,b,c}, Julia Aschenborn^d, Piet Beytell^e, Bettina Wachter^c,
Joerg Melzheimer^c, Sonja Dumendiak^b, Bianka Ruffler^a, Ute Mackenstedt^{b,g}, Peter Kern^f,
Thomas Romig^{b,g}, Marion Wassermann^{b,g,*}

^a School of Veterinary Medicine, University of Namibia, Neudamm Campus, Windhoek, Namibia

^b University of Hohenheim, Department of Parasitology, Stuttgart, Germany

^c Leibniz Institute for Zoo and Wildlife Research, Department of Evolutionary Ecology, Berlin, Germany

^d University of Zurich, Institute of Parasitology, Zurich, Switzerland

^e Directorate of Scientific Service, Ministry of Environment Forestry and Tourism, Windhoek, Namibia

^f University Hospital Ulm, Department of Medicine III, Ulm, Germany

^g University of Hohenheim, Center of Biodiversity and Integrative Taxonomy, Stuttgart, Germany

ARTICLE INFO

Keywords:

Echinococcus
Wildlife
Africa
Namibia

ABSTRACT

An opportunistic survey for *Echinococcus* spp. in wild mammals was conducted in seven distinct study areas throughout Namibia, representing all major ecosystems, between 2012 and 2021. In total, 184 individually attributable faeces and 40 intestines were collected from eight species of carnivores, and 300 carcasses or organs of thirteen species of ungulates were examined for *Echinococcus* cysts. Nested PCR and sequencing of the mitochondrial *nad1* gene led to the identification of five species of the *Echinococcus granulosus sensu lato* complex. *Echinococcus canadensis* G6/7 was found throughout Namibia at low frequency in lions, cheetahs, African wild dogs, black-backed jackals and oryx antelopes. *Echinococcus equinus* was present only in northern Namibia, locally at high frequency in lions, black-backed jackals and plains zebras. *Echinococcus felidis* was found only in one small area in the north-east of Namibia, but with high frequency in lions and warthogs. *Echinococcus granulosus sensu stricto* was identified only in two African wild dogs in the north-east of Namibia, and *Echinococcus ortleppi* occurred in central and southern Namibia in black-backed jackals and oryx antelopes. The development of fertile cysts indicated active intermediate host roles of oryx antelopes for *E. canadensis* and *E. ortleppi*, of warthogs for *E. felidis*, and of plains zebras for *E. equinus*. Our data support earlier hypotheses of exclusive or predominant wildlife life-cycles for *E. felidis* involving lions and warthogs, and – in Namibia – for *E. equinus* involving lions and/or black-backed jackals and plains zebras. Our data further support an interlink of wild and domestic transmission for *E. ortleppi*. A possible involvement of livestock and domestic dogs in transmission of *E. canadensis* G6/7 and *E. granulosus* s.s., the two parasite species with highest zoonotic potential, is uncertain for Namibia and needs further investigation.

1. Introduction

All five cryptic species of the *Echinococcus granulosus sensu lato* cluster are known from sub-Saharan Africa, although their apparently patchy distribution within the continent as well as their transmission ecology are far from understood (Deplazes et al., 2017; Romig et al., 2017). In the largest part of African regions known to be endemic for cystic echinococcosis (CE), domestic life-cycles of *Echinococcus* spp. involving domestic dogs and livestock are well described and are assumed to be the main drivers of human infection with cystic

echinococcosis (CE) (Romig et al., 2011). Besides this, eight species of wild carnivores were found to harbour *Echinococcus* worms, and close to 25 species (depending on the species concept) of mammals, mainly ungulates, are known to be intermediate hosts (Boufana et al., 2015; Hüttner and Romig, 2009; Jenkins and Macpherson, 2003; Zaffarano et al., 2021). As most records from wildlife date back to the pre-molecular era, the identity of the *Echinococcus* species in African wildlife is mostly lacking (Deplazes et al., 2017; Hüttner and Romig, 2009; Macpherson et al., 1983; Romig et al., 2017). Data from eastern Africa, where most recent surveys for these parasites were conducted,

* Corresponding author. University of Hohenheim, Department of Parasitology, Unit Emil-Wolff-Str. 34, 70599, Stuttgart, Germany.
E-mail address: marion.wassermann@uni-hohenheim.de (M. Wassermann).

<https://doi.org/10.1016/j.ijppaw.2023.04.009>

Received 4 March 2023; Received in revised form 16 April 2023; Accepted 22 April 2023

Available online 24 April 2023

2213-2244/© 2023 The Authors. Published by Elsevier Ltd on behalf of Australian Society for Parasitology. This is an open access article under the CC BY-NC-ND license (<http://creativecommons.org/licenses/by-nc-nd/4.0/>).

suggest a complex situation. There, the sylvatic transmission of *E. felidis* involving only wild mammals coexists with domestic life-cycles of e.g. *E. granulosis sensu stricto*, causing spill-over to wild animals (Kagendo et al., 2014).

Despite a long history of wildlife research, little recent data on *Echinococcus* and CE exist from southern Africa. Most of the available data come from South Africa where high prevalence of livestock CE has been reported from some areas (Verster, 1965) and where human CE is widespread and obviously underreported (Wahlers et al., 2012). In these areas, unspecified *Echinococcus* was also found in a variety of wildlife species such as African wild dog (*Lycaon pictus*), black-backed jackal (*Lupulella mesomelas*), cape fox (*Vulpes chama*), lion (*Panthera leo*), African wild cat (*Felis lybica*), plains zebra (*Equus quagga*), hippopotamus (*Hippopotamus amphibius*), warthog (*Phacochoerus africanus*), impala (*Aepyceros melampus*), greater kudu (*Tragelaphus strepsiceros*), and African buffalo (*Syncerus caffer*) (Basson et al., 1970; Boomker et al., 1989; McCully et al., 1967; Verster and Collins 1966; Young, 1975). Molecular identification of *Echinococcus* spp. in South Africa is restricted to cysts from 32 human patients (*E. canadensis* G6/7, *E. granulosis* s.s. and *E. ortleppi*), one cow (*E. ortleppi*), one white rhinoceros (*Ceratotherium simum*) (*E. equinus*), three hippopotamus (*E. felidis*) and worms from one lion (*E. felidis*) (Halajian et al., 2017; Hüttner et al., 2008; Mogoye et al., 2013; Zaffarano et al., 2021).

Information for Namibia is scarce. A recent country-wide survey on livestock CE found low prevalence of *E. ortleppi* among commercially farmed cattle, while traditionally kept cattle in northern Namibia were frequently affected (Aschenborn et al., 2022; Schneider, 2020). In southern Namibia, *E. canadensis* G6/7 is present in sheep, but no prevalence estimate was reported (Aschenborn et al., 2022). A single case of human cardiac CE, treated in South Africa, reportedly originated from Namibia (Rossouw et al., 1992). Only a few data are available for Namibian wildlife. Blue Wildebeest (*Connochaetes taurinus*) and plains zebra from the north-east of Namibia were reported to have *Echinococcus* cysts (Verster, 1965). Unspecified *Echinococcus* cysts were also found in one of six giraffes (*Giraffa giraffa angolensis*) from Etosha National Park (NP) (Krecek et al., 1990). Namibian *Echinococcus* isolates from wildlife determined to species level are limited to *E. equinus* from a mountain zebra (*Equus zebra hartmannae*) from “S W Africa” (referring to South West Africa which was the former name of Namibia from 1915 to 1990) (Kumaratilake et al., 1986), and *E. ortleppi* recovered from an unspecified zebra species from Namibia (Obwaller et al., 2004). A purely sylvatic life-cycle of *E. equinus* was recently discovered in the Etosha NP involving plains zebras (*Equus quagga burchelli*), lions and black-backed jackals (Wassermann et al., 2015). The cycle is apparently maintained by lions hunting zebras, and by black-backed jackals scavenging on zebras killed by other predators or disease.

The current survey, covering a wide range of mammals and locations in Namibia, is the first study on host range and distribution of different *Echinococcus* spp. in Namibian wildlife and the first large-scale molecular study in southern Africa. Based on opportunistic sampling, this study provides baseline information for systematic epidemiological surveys, the interaction of domestic and wild mammals for CE transmission and the potential impact on human health.

2. Material and methods

2.1. Study areas

Namibia is located in the far southwest of sub-Saharan Africa, bordering Angola, Zambia, Botswana and South Africa. The west of the country is framed by the Atlantic Ocean where the cold Benguela current determines the climate. The cold dry air along the coast creates a gradient of rainfall with 0 mm annual rainfall along the coast to more than 600 mm of rain in the far north-east of the country. This gradient creates a large diversity of ecosystems, ranging from the extremely arid Namib Desert to savannah forest. Our study sites cover all major types of

ecosystems in Namibia (Fig. 1).

Two of the seven study sites, the Mudumu/Bwabwata/Nkasa Rupara complex and the eastern floodplains, were located in the north-eastern Zambezi region, formerly known as the Caprivi strip. This region is part of the KAZA TFCA (Kavango-Zambezi Transfrontier Conservation Area), a complex of conservation areas in Namibia, Angola, Zambia, Botswana and Zimbabwe.

The Mudumu/Bwabwata/Nkasa Rupara complex includes three NPs, i.e. Mudumu (1010 km²), Bwabwata (6100 km²), and Nkasa Rupara NP (320 km², previously known as Mamili NP) as well as surrounding communal farmland and communal conservancies (wildlife protection areas managed by the local communities). Average summer maximum and minimum are 36 °C and 21 °C, respectively, with winter maximum and minimum ranging between 25 °C and 8 °C. Highest temperature can occasionally exceed 40 °C in summer but sub-zero temperatures are very rare during winter. The average rainfall is 680 mm/a and is limited to the summer months (Katima Mulilo weather station, www.weather-atlas.com).

The elevation of the Zambezi region ranges between 911 m and 1308 m above sea level with no mountains. No fences exist in this area (except for parts of the Botswana border), thus there is extensive mixing of wildlife from the NPs with domestic animals, and wildlife migration is possible in most parts of this study site and within the KAZA TFCA. In the communal farmland, extensive cattle farming is practised, and some farmers keep small livestock, complemented to a lesser extent by horticulture.

The eastern floodplains consist of a combination of agricultural land and conservancies. Wildlife is common, and large numbers of animals migrate between Namibia and Botswana through the Chobe river system, which forms part of the KAZA TFCA. The floodplains are an important feeding area during the dry season both for wildlife and livestock, resulting in wildlife, domestic animals and humans at close proximity. This study site was close to the Mudumu/Bwabwata/Nkasa Rupara complex and vegetation and climate were very similar.

The Khaudum/Mangetti study site included the Khaudum and Mangetti NPs. Rainfall is limited to the summer period with an average of 450 mm/a. The warmest month of the year is October with an average high of 34 °C, and the coldest month is July with an average low of 5 °C (Tsumkwe weather station, www.weather-atlas.com). Khaudum NP is only fenced along the border to Botswana, but elephant damage to the fence is common and the carnivores cross the fence at any place (Aschenborn, unpublished data). The area is located at an altitude of 1053 m to 1244 m above sea level. It has a size of 3842 km² and is situated in the tree and shrub savannah biome.

The Mangetti NP, 420 km² in size at an altitude of 1138 m to 1213 m above sea level, is situated in the eastern Kalahari woodlands, surrounded by a wildlife fence. Also here, carnivores are not retained by the fence (Aschenborn, unpublished data). Wildlife species composition is similar to the Khaudum NP and includes African wild dog, leopard (*Panthera pardus*), spotted hyena (*Crocuta crocuta*), caracal (*Caracal caracal*) blue wildebeest, oryx (*Oryx gazella*), kudu, sable antelope (*Hippotragus niger*), steenbok (*Raphiceros campestris*) and occasionally elephant (*Loxodonta africana*). Between and around these two NPs is communal farmland with the same farming practices as described for the study sites in the Zambezi region.

Central Namibia is dominated by commercial farming, land is owned individually and usually fenced with cattle fences that do not restrict wildlife. The average farm in central Namibia is 50 km² but can exceed 300 km² in the southern area, where weather conditions are less favourable for farming due to low rainfall. In the far south this can be less than 100 mm/a, whereas in the north central area it can exceed 600 mm/a. Windhoek, the capital of Namibia and the centre of the study site is at an elevation of 1500 m above sea level. Temperatures show an average high of 30 °C in October and November and an average low of 6 °C in July. In parts of the study site, the temperatures can drop below zero for some nights and frost is common. Most farms are dominated by

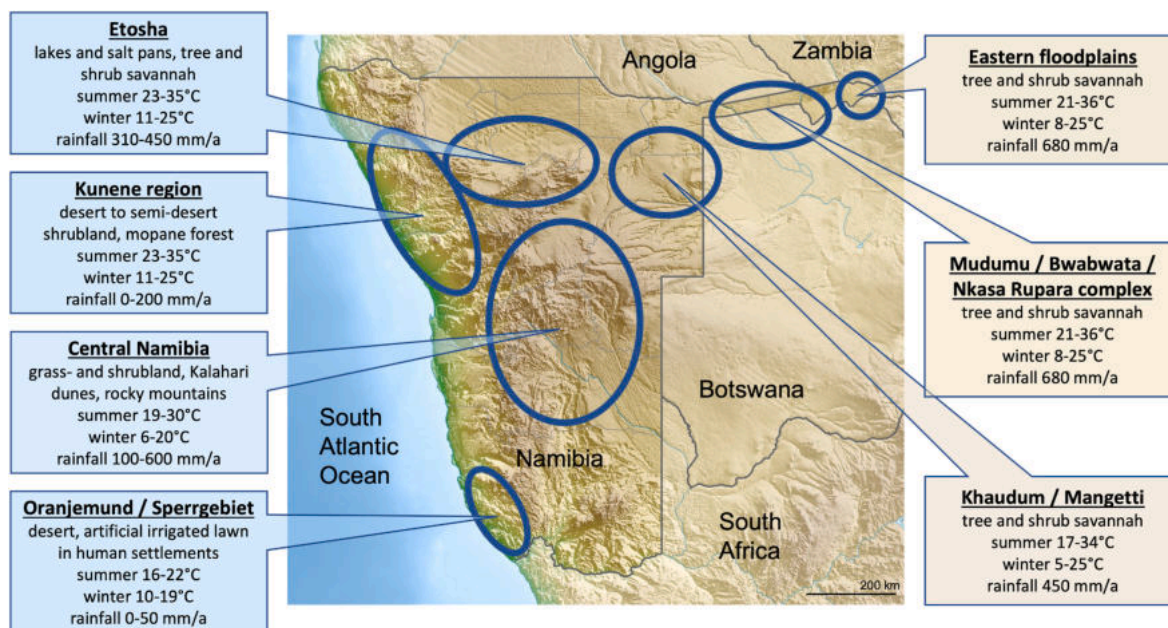


Fig. 1. Location of the seven study sites in Namibia (Source of modified map https://de.wikipedia.org/wiki/Datei:Namibia_relief_location_map.jpg).

extensive cattle rearing, but goats and sheep are also kept. On livestock farms, also wild ungulates are still common, and carnivores are present at low density, except for lions and African wild dogs which are not present. Another form of land use in central Namibia is wildlife farming. These are well fenced areas with high numbers and diverse wildlife species used for sport hunting, meat production and/or ecotourism.

The Kunene region covers the north-western part of Namibia. This study site included the Skeleton Coast NP (16,390 km²) extending from the sea, where rainfall can be completely absent, to the inland, where rain seldom exceeds 200 mm/a, with dunes, mountains and semi desert scrublands and mopane forests. Here, communal farming is nomadic due to the fluctuation in grass growth. Both cattle and small-stock are kept. There are no fences, and wildlife densities are low. Since wildlife animals roam freely, they come occasionally into contact with livestock. Wildlife is protected and utilized through the conservancy management system. In winter, average low temperature drops to 11 °C and average highs reach 35 °C in October (Kamanjab weather station, www.weather-atlas.com), but can reach high forties on some days.

The Etosha study site (23,000 km²) included the national park and some farms in direct proximity of the protected area. The Etosha NP is entirely fenced, thus inhibiting wildlife migration, although the fence is partly damaged and carnivores and elephants pass the fence regularly. The Etosha NP spans a west-eastern average rainfall gradient from 310 to 450 mm/a. The rain is limited to the summer months and peaks around December. The hottest month is October with a high average of 35 °C and the coldest month is July with a low average of 11 °C (Okaukuejo weather station, www.weather-atlas.com). There are no livestock and domestic dogs in the Etosha NP and in those adjacent farms that were included in the study site.

The Oranjemund/Sperrgebiet study site was located in the south of Namibia. Oranjemund is a small coastal town in a large diamond mining area with restricted access and no livestock farming. The only domestic animals are dogs and cats. The area is extremely arid with annual rainfall between 0 mm and <50 mm. Irrigated public gardens and a golf course attract wildlife from the surrounding desert, which can be present at unnaturally high densities. Access to the town is limited and controlled by the diamond mining company. The mining concession is not utilized, and large areas are untouched and left to free roaming wildlife. The wildlife density is extremely low and only desert adapted species such as oryx or brown hyena (*Hyaena brunnea*) are found here.

The cold Benguela current influences the temperature of the town which average between 13 °C and 18 °C throughout the year.

2.2. Samples from definitive hosts

A total of 184 faecal samples from eight different species of large and medium-sized carnivores were collected between 2012 and 2021. The samples were collected shortly after individual animals were observed to defecate or rectally when animals were immobilised during routine work for other purposes such as relocation conducted by the Namibian Ministry of Environment, Forestry and Tourism (MEFT). In addition, intestines were recovered from 40 black-backed jackals that had been legally hunted on commercial farmland. Samples were either stored at –20 °C or in 75% ethanol at room temperature. Before further processing, the samples stored at –20 °C were subjected to –80 °C for at least seven days to inactivate potentially infectious *Echinococcus* eggs.

2.3. Samples from intermediate hosts

All cyst materials for this study were collected during an opportunistic survey of 300 animals of 13 species hunted or culled under official MEFT projects, during legal hunting or from animals shot as part of the legal off-take as regulated through the Namibian “Nature Conservation Ordinance 4 of 1975” legislation between 2012 and 2021. Liver, lungs, and other organs were carefully inspected for the presence of cystic lesions. Cysts were counted, measured (maximum diameter) and the content was microscopically examined for protozoocysts. The condition of cysts without protozoocysts was visually assessed as sterile (apparently viable with clear fluid, detachable germinal layer) or non-viable (calcified, caseated). On some occasions, only organs were available for examination. Cyst content (protozoocysts or pieces of cyst wall) were transferred into 75% ethanol, or first frozen and later transferred into ethanol, and stored at room temperature.

2.4. Sample preparation

Taeniid eggs were retrieved from faecal material through zinc chloride flotation (Mathis et al., 1996). This was done by suspending no more than 2 cm³ of faecal material in 1 x PBS and 0.3% Tween 20. The suspension was centrifuged for 10 min at 1600 g. The supernatant was

Table 1
Number of potential host species examined, and number infected with *Echinococcus* spp. in brackets from the various locations of Namibia. EC = *E. canadensis* G6/7, EE = *E. equinus*, EF = *E. felidis*, EG = *E. granulosus sensu stricto*, EO = *E. ortleppi*.

Host species	Central Namibia	Kunene Region	Etosha	Khaudum/Mangetti	Mudumu/Bwabwata/Nkasa Rupara complex	Eastern floodplains	Oranjemund/Sperrgebiet	Total
Carnivores (<i>Echinococcus</i> worms or eggs in faecal samples)	n examined (n positive)							
Lion (<i>Panthera leo</i>)	–	11 (5 EE)	11 (4 EE)	7 (1 EC)	20 (2 EC, 7 EF)	–	–	49 (3 EC, 7 EF, 9 EE)
Leopard (<i>Panthera pardus</i>)	4 (–)	1 (–)	10 (–)	–	2 (–)	–	–	17 (–)
Cheetah (<i>Acinonyx jubatus</i>)	32 (3 EC)	3 (–)	4 (–)	–	–	–	–	39 (3 EC)
Caracal (<i>Caracal caracal</i>)	4 (–)	–	–	–	–	–	–	4 (–)
Spotted hyena (<i>Crocuta crocuta</i>)	–	–	9 (–)	6 (–)	1 (–)	–	–	16 (–)
Brown hyena (<i>Hyaena brunnea</i>)	1 (–)	3 (–)	1 (–)	–	–	–	8 (–)	13 (–)
Black-backed Jackal (<i>Lupulella mesomelas</i>)	60 ^a (1 EC, 2 EO)	1 (–)	7 (2 EE)	–	–	–	5 (2 EC)	73 (3 EC, 2 EE, 2 EO)
African wild dog (<i>Lycaon pictus</i>)	–	–	–	8 (1 EG)	5 (1 EG, 1 EC)	–	–	13 (1 EC, 2 EG)
Total	101 (4 EC, 2 EO)	19 (5 EE)	42 (6 EE)	21 (1 EC, 1 EG)	28 (1 EG, 3 EC, 7 EF)	–	13 (1 EC)	224 (10 EC, 2 EG, 7 EF, 11 EE, 2 EO)
Herbivores (metacestodes)								
Black Rhinoceros (<i>Diceros bicornis</i>)	–	1 (–)	2 (–)	–	–	–	–	3 (–)
Plains Zebra (<i>Equus quagga burchellii</i>)	–	–	22 (18 EE)	–	2 (–)	19 (9 EE)	–	43 (27 EE)
Mountain Zebra (<i>Equus zebra hartmannae</i>)	–	5 (–)	–	–	–	–	–	5 (–)
Hippopotamus (<i>Hippopotamus amphibius</i>)	–	–	–	–	–	3 (–)	–	3 (–)
Warthog (<i>Phacochoerus africanus</i>)	83 (–)	–	–	2 (–)	7 (4 EF)	–	–	92 (4 EF)
African Buffalo (<i>Syncerus caffer</i>)	–	–	–	–	9 (–)	–	–	9 (–)
Kudu (<i>Tragelaphus strepsiceros</i>)	12 (–)	–	–	3 (–)	5 (–)	–	–	20 (–)
Sable antelope (<i>Hippotragus niger</i>)	–	–	–	–	1 (–)	–	–	1 (–)
Oryx antelope (<i>Oryx gazella</i>)	58 (4 EO)	1 (1 EC)	15 (–)	–	–	–	4 (1 EC, 2 EO)	78 (2 EC, 6 EO)
Impala (<i>Aepyceros melampus</i>)	–	–	–	–	2 (–)	–	–	2 (–)
Springbuck (<i>Antidorcas marsupialis</i>)	–	–	14 (–)	–	–	–	–	14 (–)
Red Hartebeest (<i>Alcelaphus caama</i>)	28 (–)	–	–	–	–	–	–	28 (–)
Wildebeest (<i>Connochaetes taurinus</i>)	–	–	–	–	–	2 (–)	–	2 (–)
Total	181 (4 EO)	7 (1 EC)	53 (18 EE)	5 (–)	26 (4 EF)	24 (9 EE)	4 (1 EC, 2 EO)	300 (2 EC, 27 EE, 4 EF, 6 EO)

^a All positive cases detected at necropsy of 40 jackals; additional 20 fecal samples were negative.

discarded and the pellet re-suspended in 15 ml zinc chloride solution with the specific gravity of 1.45 g/cm³ after which the new suspension was centrifuged for 30 min at 400 g. The resulting supernatant was passed through sieves with mesh size 50 µm and 20 µm respectively (Mathis et al., 1996). The eggs passed the 50 µm sieve and were retained by the 20 µm sieve. The captured particles were washed off the latter sieve with distilled water. The collected water was again centrifuged at 1600 g for 10 min and the resulting pellet suspended in 1–2 ml distilled water, transferred to 2 ml tubes, and stored at –20 °C until further examination. The egg solution was examined under an inverse microscope for taeniid eggs. Single taeniid eggs were transferred in a volume of 1 µl via pipette into 9 µl of 0.02 M NaOH solution and lysed at 95 °C for 10 min (Nakao et al., 2003). The lysate was used directly as template in the following PCRs.

Carnivore intestines were opened longitudinally after thawing, coarse material removed, and the mucosa was deeply scraped using microscope slides. Slides with scrapings were transferred to and pressed onto petri dishes and examined under a stereomicroscope. Identified *Echinococcus* worms were transferred to tubes containing 75% ethanol and stored at room temperature until further processing.

Single worms, or in case of cyst material, protoscoleces or small tissue pieces (0.5 mm³) of the cysts were each transferred to 30 µl of 0.02 M NaOH solution and lysed at 95 °C for 15 min. The lysate was used directly as template for the following PCRs.

2.5. DNA amplification and sequencing

For species identification of the cyst, worm and taeniid egg samples the complete mitochondrial NADH dehydrogenase subunit 1 (*nad1*) gene was amplified via nested PCR. For the first PCR, sterile tubes were prepared with a mixture of 25 µl containing 10 mM Tris-HCl (pH 8.3), 50 mM KCl, 2 mM MgCl₂, 200 µM of each dNTPs, 6.25 pmol of each primer and 0.625 U of Taq polymerase. One microliter of the cyst, worm or egg lysate was added to the PCR-mixture as template. The volume of the nested PCR reaction mixture was 50 µl and consisted of 10 mM Tris-HCl (pH 8.3), 50 mM KCl, 2 mM MgCl₂, 200 µM of each dNTPs, 12.5 pmol of each primer and 1.25 U of Taq polymerase and 2 µl of the

product of the primary PCR as template. The following primers were used in the primary PCR: forward primer 5'-TGG AAC TCA GTT TGA GCT TTA CTA-3' and reverse primer 5'-ATA TCA AAG TAA CCT GCT ATG CAG-3' and for the nested PCR 5'-ATT AAA AAT ATT GAG TTT GCG TC-3' and 5'-TCT TGA AGT TAA CAG CAT CAC GAT-3' as forward and reverse primers respectively (Hüttner et al., 2008). Amplification conditions for both PCRs were an initial denaturation at 94 °C for 5 min followed by 35 cycles with denaturation at 94 °C for 30 s, annealing at 55 °C for 30 s, elongation at 72 °C for 60 s and a final elongation at 72 °C for 5 min. Amplification results were detected on a 1.5% agarose gel stained with GelRed™. Successfully amplified cyst, worm or taeniid egg amplicons were purified with High Pure PCR Product Purification Kit (Roche) and sent off for sequencing (GATC Biotech AG, Konstanz, Germany). The sequences were analysed using GENTle V1.9.4 program (Manske M., University of Cologne, Germany) and compared with GenBank entries using the NCBI basic local alignment search tool (BLAST) for identification of the causative species.

3. Results

Five *Echinococcus* species were identified in four species of carnivores, and four *Echinococcus* species were identified in three species of ungulates. In all seven study sites we found at least one *Echinococcus* species (Table 1, Fig. 2). When stratified to host species and geographical spread, the occurrence of the parasite species was highly uneven.

Echinococcus canadensis (G6/7) had the widest geographical spread and was present in five of seven study sites. It also had the highest number of host species and was detected in five of the 21 investigated species. Across all study sites, *E. canadensis* G6/7 was recorded in 3/49 lions, 3/39 cheetahs, 2/5 black-backed jackals and 1/13 African wild dogs (faecal prevalence), and 1/40 (2.5%) necropsied black-backed jackals. Two out of 78 oryx antelopes were found with metacestodes. One oryx had a 1.5 cm (maximum diameter) fertile cyst in the liver, the second oryx had multiple fertile cysts in the lungs, 2–5 cm in maximum diameter, and >10 small (<1 cm) sterile cysts (viable without protoscoleces) in the liver. Ten of eleven collected fertile cysts were *E. canadensis* G6/7 and one *E. ortleppi*.

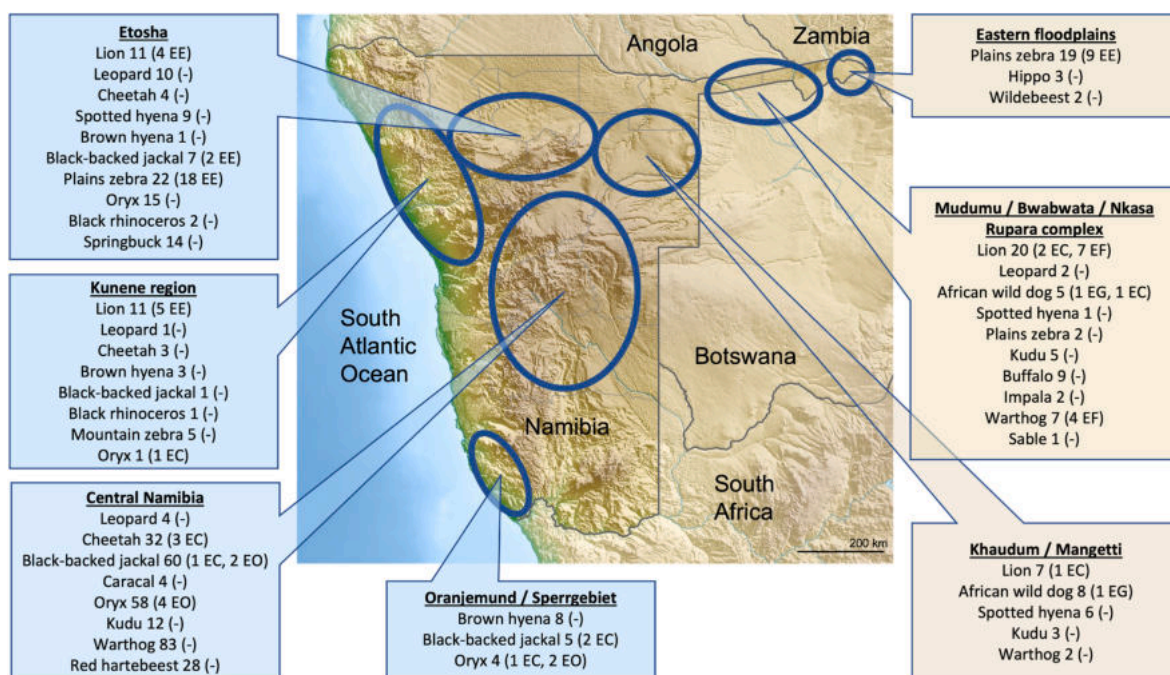


Fig. 2. Species and numbers of examined animals in the seven study sites; in brackets numbers of infected animals and causative *Echinococcus* sp. (EC = *E. canadensis*, EE = *E. equinus*, EF = *E. felidis*, EG = *E. granulosus sensu stricto*, EO = *E. ortleppi*) (Source of modified map https://de.wikipedia.org/wiki/Datei:Namibia_relief_locaiton_map.jpg).

Echinococcus equinus occurred in three of the study sites in northern Namibia (Kunene region, Etosha, eastern floodplains) in 9/22 lions, 2/8 black-backed jackals and 27/43 plains zebras. A total of 61 cysts, 55 isolated from the liver and six from the lungs, from the 27 infected plains zebras were sequenced, nine failing to give results. Cysts attained large sizes up to 12–16 cm in diameter. Eleven cysts were fertile, 35 sterile and 15 non-viable (calcified).

Echinococcus felidis only occurred in the Mudumu/Bwabwata/Nkasa Rupara complex in the north-eastern Zambezi region. At the endemic site it was frequent, eggs being present in seven of 20 lion faeces, while four of seven warthogs had a total of six cysts. All cysts were located in the liver with a maximum diameter of 1–3 cm, five cysts were fertile.

Echinococcus granulosis s.s. was found in 2/13 African wild dogs in the Khaudum/Mangetti (1/8) and Mudumu/Bwabwata/Nkasa Rupara complex (1/5) study sites in north-eastern Namibia, but in no other region or host species.

Echinococcus ortleppi was only found in the central Namibia and Oranjemund/Sperrgebiet study sites. In central Namibia, worms of *E. ortleppi* were present in 2/40 (5.0%) necropsied black-backed jackals, while 20 faecal samples from that study site were negative for eggs, and cysts could be detected in 4/58 oryx antelopes. In the Oranjemund study site, two of only four examined oryx had *E. ortleppi* cysts. One fertile cyst was present in an animal co-infected with *E. canadensis* G6/7. Another oryx had a fertile 3.5 cm lung cyst of *E. ortleppi*, and a third oryx had multiple small (≤ 1 cm) sterile cysts in the liver, of which two could be amplified and identified as *E. ortleppi*. The remaining three oryx had multiple fertile *E. ortleppi* cysts in the lungs and liver ranging from 1 to 3.5 cm in maximum diameter.

4. Discussion

4.1. General considerations

Here we present the most comprehensive molecular survey of African wild mammals for host range and geographical spread of different species of *Echinococcus*, covering eight species of medium to large carnivores as potential definitive hosts, and thirteen species of ungulates as potential intermediate hosts. The only comparable survey was done in Kenya, which was however limited to environmental faecal samples of lions, leopards and spotted hyenas (Kagendo et al., 2014). Compared with Kenya, where only *E. felidis* and *E. granulosis* s.s. were discovered in 832 faecal samples from six different conservation areas, we uncovered a surprising diversity of *Echinococcus* in Namibian wildlife, identifying all five species of *Echinococcus* that are known – worldwide – to cause cystic echinococcosis in humans and/or animals. As all samples in this study were obtained opportunistically in the context of other investigations and no mammal was manipulated, caught or sacrificed for the study, we did not achieve comprehensive geographical coverage of Namibia for all potential host species. This is also the reason for the unequal number of sampled animals per host species, resulting in very low numbers for some. Consequently, no attempts are made to provide prevalence estimates as sample sizes became very small after stratification according to host and location. Other reasons for not reporting prevalences are that in some cases not all cysts found in an animal could be sampled and examined and that only a subset of eggs isolated from faeces were analysed. Thus, there is a possibility that double infections may have gone undetected. As for definitive host species, in most cases only faeces were available, and eggs were isolated by flotation to perform single egg analyses. It is known that the sensitivity of this method is limited and that, as a result, the true prevalence is certainly much higher than was detected here (Marchiori et al., 2023).

Namibia is very diverse concerning climate, vegetation types, human population density and presence of wildlife conservation areas. Therefore, wild mammals are unequally distributed across the country. Lions, as an example, are present in discrete populations in the north of Namibia only, which means that a parasite that depends on lions as

definitive hosts will not be widespread in the country, while parasites with a wider host range are more likely to be recovered from a diverse set of localities. This is precisely the pattern that was observed in the study: records of *E. felidis* and *E. equinus*, which apparently depend on lions and zebras, respectively, were only recorded in the north of Namibia, while *E. canadensis* G6/7, known to have a rather low host specificity (Romig et al., 2017), was found in all regions of the country (though not in all study sites). *Echinococcus granulosis* s.s. and *E. ortleppi* were more sporadically found in Namibian wildlife and their records may represent spill-overs from domestic life-cycles involving dogs and livestock.

4.2. Life cycles and hosts

Five *Echinococcus* spp. were found in wild mammals in Namibia, the highest known diversity in wildlife on the African continent followed by Kenya (Kagendo et al., 2014; Romig et al., 2011) and representing all *Echinococcus* spp. known to occur in Africa (Deplazes et al., 2017; Miambo et al., 2020; Mogoye et al., 2013). This high diversity in Namibia is unlikely to be extraordinary but might reflect the scarcity of records in other countries, at least for southern Africa. All species we found – except *E. felidis* – are primarily known from domestic life cycles across the world. Their occurrence in southern African wild mammals (and their transmission in wildlife cycles without the input of domestic animals) could be the result of host switch (or ecological niche fitting) following the anthropogenic introduction of the parasites together with domestic cattle, pigs, sheep and horses that is documented since the 16th century (Swart et al., 2010; Mitchell, 2022). Whether or not this is the case needs detailed phylogenetic analysis and comparison of isolates derived from both wildlife and livestock throughout sub-Saharan Africa and elsewhere, which is currently under study.

Echinococcus canadensis G6/7 proved to be the most widespread taxon of *Echinococcus* in Namibia. It was found in five of the seven study sites and in the largest number of definitive host species (lion, cheetah, African wild dog and black-backed jackal). Only oryx antelopes were confirmed as intermediate hosts. Due to the low number of other wild bovids examined, it remains to be confirmed whether oryx antelopes are key hosts for this parasite. In the Oranjemund/Sperrgebiet, a life-cycle may exist through black-backed jackals scavenging from oryx carcasses. Infection sources for cheetahs, lions, wild dogs and jackals in central and/or north-eastern Namibia are unknown, but oryx antelopes are present on many of the central Namibian farms. In contrast, oryx are absent in the north-east of Namibia, where wild dogs and lions were found infected in Mudumu/Bwabwata/Nkasa Rupara complex and Khaudum/Mangetti NPs. Domestic sheep were recently reported with fertile infections of *E. canadensis* G6/7 in the southern Namibian farming region (Aschenborn et al., 2022), but sheep are infrequently kept in central and northern Namibia and are therefore unlikely to be an important source of infection. Interestingly, the sheep isolates showed 100% sequence identity of the mitochondrial *nad1* gene with our Oranjemund/Sperrgebiet oryx isolate (Aschenborn et al., 2022). This suggests a spill-over between livestock and wildlife, at least in southern Namibia. A domestic life-cycle of *E. canadensis* G6/7, as known from other African regions (Romig et al., 2017), has never been identified in southern Africa, but the presence of human patients in South Africa (Mogoye et al., 2013) suggests its existence. The wide distribution of *E. canadensis* G6/7 in Namibia supports the low host specificity which is well described for this taxon (Romig et al., 2017). While lions and African wild dogs are limited mainly to NPs and protected areas, cheetahs and black-backed jackals are still widely distributed over most of Namibia. Cheetahs are known for their huge home ranges between 379 and 1595 km² depending on sex and spatial tactic (Melzheimer et al., 2018), thus coming into contact with a large variety of species. Interestingly, genetic analyses of cysts from the Namibian oryx revealed a close affinity to pig isolates from Corsica (France) rather than to Sudanese, Kenyan and Ethiopian isolates of the “camel strain” or “G6 cluster”

(Addy et al., 2017) indicating a complex biogeographical history of this parasite. This raises the question whether we observe a primary wildlife cycle, or whether wildlife infection is the result of spill-over from domestic animals and subsequent host switches. More sampling throughout sub-Saharan Africa will be necessary to come to a conclusion. There is no confirmed record of *E. canadensis* G6/7 from wild animals of any other African country. Early reports of infected scimitar-horned oryx (*Oryx dammah*) in Chad (Graber et al., 1969) may also refer to this species, since it is the only taxon of *Echinococcus* that is today frequent in the northernmost parts of sub-Saharan Africa (Deplazes et al., 2017).

A sylvatic life-cycle of *E. equinus* was described in the Etosha NP, where a transmission system involving lions and plains zebras was suggested to be complemented by black-backed jackals acquiring infection by scavenging on zebra carcasses (Wassermann et al., 2015). Our data confirm that these three species were infected with *E. equinus*, and the high frequency of this parasite in Etosha NP supports the sylvatic life-cycle suggested previously. In the present study, plains zebras were also found frequently infected (9/19) in the eastern floodplains in the north-east of the country. Lions visit this area only infrequently as it is not formally protected. However, movement data show that this zebra population migrates deep into Botswana during the rainy season, where transmission to and from lions may occur, e.g., in Nxai Pan NP (Naidoo et al., 2016). Two of four lion faecal samples from Botswana contained eggs of *E. equinus*, which supports this hypothesis (Aschenborn, unpublished data). The haplotypes of *E. equinus* found in the eastern floodplains were identical to those reported from Etosha NP (data not shown; Wassermann et al., 2015). There are no domestic dogs, horses and donkeys in Etosha NP nor on those adjacent farms, where samples were collected, thus a transmission from domestic animals is unlikely. This cannot be excluded for the eastern floodplains where wildlife is exposed to domestic dogs, horses and donkeys. The transmission from domestic animals might be low, though, because 147 faecal samples of domestic dogs collected in this study site were negative for *E. equinus* and only one sample contained *E. ortleppi* (Schneider, 2020). From the Kunene region in north-western Namibia, 5/11 lion faecal samples contained eggs of *E. equinus*, whereas five examined mountain zebras were not infected. Plains zebras do not occur in the Kunene region, but an older publication reports on a fertile cyst of *E. equinus* from a mountain zebra from “S W Africa” (sic), proving the host competence (Kumaratilake et al., 1986). This suggests that mountain zebras support transmission in the Kunene region. In Kruger NP in South Africa, 60% of plains zebras were found infected with what was then thought to be *E. felidis* (Young, 1975). It is highly likely that the observed parasite was rather *E. equinus*, but confirmation will necessitate to revisit the Kruger Park zebra population. The description that “in zebra many large cysts often replace a considerable proportion of liver parenchyma” (Young, 1975) and that liver cysts from zebras in Kruger NP “containing as much as 1000 ml of fluid and thousands of scoleces” (McCully et al., 1969) match the picture found in Namibian zebras with cysts as large as 12 × 16 cm and multiple large cysts, of which only 25% were non-viable, occurring in the same animal. The presence of *E. equinus* in the Kruger NP was recently confirmed by the identification of a fertile cyst in a white rhinoceros (*Ceratotherium simum*) (Zaffarano et al., 2021). Interestingly, *E. equinus* was never found in lions in various conservation areas in Kenya where large zebra populations are present (Kagendo et al., 2014), possibly due to the general rarity of this parasite in eastern Africa (Mulinge et al., 2023).

In Namibia, *E. felidis* seems to be geographically restricted to the northeast of Namibia, as it was only found in Nkasa Rupara NP, a small conservation area bordering Botswana, where seven out of twenty lions and four out of seven warthogs were infected. In addition, one of four lion faeces from Botswana also contained *E. felidis* eggs (Aschenborn, unpublished). This adds evidence that warthogs, which are very common in the Nkasa Rupara NP, are crucial as intermediate hosts for this parasite. Also the fact that five out of six cysts were fertile indicates the

good suitability of warthogs for this parasite. However, warthogs are widespread in the country, and the absence of *E. felidis* in the other study sites in warthogs (central Namibia and Khaudum/Mangetti NPs) and in lions (Etosha NP, Kunene region and Khaudum/Mangetti NPs) suggest that *E. felidis* only occurs in the north-east of Namibia. Apart from the description of the species based on lion samples from northern South Africa and their subsequent molecular confirmation (Hüttner et al., 2008; Verster, 1965) nothing was known about *E. felidis* in other parts of southern Africa until a recent publication on *E. felidis* in hippopotamus (Halajian et al., 2017). Hippopotamuses are also common in the Nkasa Rupara NP but we did not screen any hippopotamus from this particular study site. More information is available for East Africa, where *E. felidis* seems to be frequent and widespread in NPs and other wildlife conservation areas of Kenya and Uganda. Among others, it occurs in five of six Kenyan conservation areas in lions at faecal prevalences of 0.9–18.2% (Hüttner and Romig, 2009; Kagendo et al., 2014). An older description of a life-cycle of *Echinococcus* sp. involving lions, warthogs and bush pigs (*Potamochoerus porcus*) in the Central African Republic may also refer to this species (Graber and Thal, 1980). Spotted hyenas have been described as definitive hosts of *E. felidis* in addition to lions in eastern Africa (Hüttner and Romig, 2009; Kagendo et al., 2014). The absence of this parasite in both Namibian hyena species is not relevant for this study, as hyenas were not sampled in the endemic Nkasa Rupara NP.

Two African wild dogs, one from the Mudumu/Bwabwata/Nkasa Rupara complex and one from the Khaudum/Mangetti NPs provided the only isolates of *E. granulosis* s.s. in this study. Worldwide, this is the most widespread and frequent agent of CE, and has the largest impact on human health (Alvarez Rojas et al., 2014; Cardona and Carmena, 2013). It is principally transmitted between dogs and livestock, but numerous reports testify spill-overs into wild mammal populations (Jenkins and Macpherson, 2003). In Kenya, infections of lions and spotted hyenas seem to be frequent and it has also been found in western white-bearded wildebeest (*Connochaetes mearnsi*) and warthogs (Hüttner and Romig, 2009; Kagendo et al., 2014). Yet, there is no conclusive evidence for a sylvatic transmission in eastern Africa that is maintained without the input from domestic animals. The latter is facilitated by an extensive interface between livestock and wildlife in and around the conservation areas (Kagendo et al., 2014). For southern Africa, the evidence for the presence of this parasite is limited to reports of human CE cases from South Africa (Mogoye et al., 2013). It may be rare (or restricted to local foci) even in domestic settings. African wild dogs were reported in various older studies to be infected with *E. granulosis* *sensu lato* in East and South Africa (Nelson and Rausch, 1963; Verster and Collins, 1966; Verster, 1965). One faecal sample that tested positive in this study for *E. granulosis* s.s. was collected in the Bwabwata NP, where members of the San community are legally settled in the park and keep goats and some cattle. It was not possible to extensively sample these livestock animals, but four animals were sampled so far, with negative result (Aschenborn et al., 2022). Thus, at this stage no intermediate host was identified in this ecosystem.

Oryx antelopes sampled in Oranjemund and central Namibia were found infected with *E. ortleppi*, which is a new report of a competent intermediate wildlife host for this parasite. In addition, two out of 40 necropsied black-backed jackals from the central Namibian farming region had *E. ortleppi* worms. Worldwide, *E. ortleppi* is typically transmitted between domestic dogs and cattle (Romig et al., 2017), and no sylvatic life-cycle has been described from anywhere. A recent survey of livestock and dogs in Namibia found cattle infection with *E. ortleppi* to be widespread at 1.65% prevalence in central and southern Namibia, and more frequently (three of twelve examined cattle) in the northern part of the country, where also one dog infection was recorded among 118 faecal samples (Aschenborn et al., 2022; Schneider, 2020). For central Namibia, the black-backed jackal infections may be explained by them scavenging on cattle carcasses. On the large farms in central Namibia, dead animals are often not found by humans and, in the absence or at low density of spotted and brown hyenas, black-backed jackals are the

main scavenger in this ecosystem. Apart from cattle carcasses, jackal infection could also originate from the carcasses of oryx that were found to be more frequently infected than cattle. The hypothesis of a wildlife cycle between black-backed jackals and oryx should be tested by estimating the relative frequencies of cattle and oryx carcasses available for scavenging. In contrast to central Namibia, no domestic intermediate hosts are present in the Oranjemund/Sperrgebiet study site, so that a local cycle between oryx antelopes and carnivores, possibly black-backed jackals or domestic dogs, must exist in this area. One earlier report mentioned zebra to be an intermediate host in Namibia (Obwaller et al., 2004). However, in our study no zebras were found to be infected with *E. ortleppi* despite extensive sampling even in areas of high cattle density where *E. ortleppi* is known to be present. This raises doubts on the significance of zebras as intermediate hosts for this parasite species in Namibia. In conclusion, it appears from our restricted data that the life-cycle of *E. ortleppi* in Namibia runs at an interface between wild and domestic animals.

In summary, there is strong involvement of wild mammals in the transmission of *Echinococcus* taxa in Namibia, and the presence of the five *Echinococcus* species is highly structured both spatially and according to host species. The life-cycles of *E. felidis* and *E. equinus* appear to be entirely or predominantly sylvatic, while infections of wildlife with *E. granulosus* s.s. and *E. ortleppi* may, to an unknown extent, be due to spill-over from domestic transmission. For *E. canadensis* G6/7, the most widespread species, wild mammals seem to be the principal hosts, but there is also some interaction with livestock. As many putative host species were only sampled in small numbers, we cannot provide a host list for the various *Echinococcus* species. Yet, the study provides interesting new data on the host role of several large mammal species. Lions were known already to be suitable definitive hosts for *E. felidis*, *E. granulosus* s.s. and *E. equinus* (Hüttner et al., 2008; Kagendo et al., 2014; Wassermann et al., 2015). In addition, we showed that lions were also infected with *E. canadensis* G6/7, which renders lions clearly as good hosts for most, if not all, agents of CE. This is an unexplained contrast to leopards, which had never been recorded as hosts of *Echinococcus* spp., and negative results for 17 animals in this study indicate a minor host role, if any, for this species. As the prey species of lions and leopards largely overlap, further investigations are needed to establish whether there is a physiological adaption of lions to infection (in contrast to most other Felidae). The findings of *E. canadensis* G6/7 in cheetahs constitute a new definitive host record for any *Echinococcus* spp., although the role of this species for transmission requires further data. It is interesting to note that no *Echinococcus* eggs were detected in 16 spotted hyenas and 13 brown hyenas. Spotted hyenas had been reported on several occasions as hosts of *Echinococcus* spp. Eggs of *E. felidis* and *E. granulosus* s.s. were found in faecal samples of spotted hyenas in Uganda and Kenya (Hüttner et al., 2009; Kagendo et al., 2014), and adult worms of *Echinococcus* spp. had also been found at necropsy in three of 19 spotted hyenas in Kenya (Nelson and Rausch, 1963).

The frequency of *Echinococcus* spp. in Namibian wildlife does have a public health aspect, as two of the recorded taxa, *E. granulosus* s.s. and *E. canadensis* G6/7, are the most important agents of human CE (Alvarez Rojas et al., 2014). Wildlife is translocated continuously throughout Namibia and to the neighbouring South Africa. There is very little consideration for potential disease spread with the exceptions of Foot and Mouth Disease, African Swine Fever and Malignant Catarrhal Fever (Namibian Animal Health Act of 2002). Considering the increasing economic importance of the game industry as well as increasing populations of livestock densities and expansion of human settlements into wildlife areas, more attention needs to be paid to the interface of wildlife, domestic animals and humans. Also, more attention is needed in analysing and managing the risk of potential diseases including CE. Very little is known about the CE situation in humans in Namibia, and most other countries of southern Africa (Miambo et al., 2020), thus further investigations are urgently needed.

Even though our survey is far from comprehensive, the data provide

a basis for further investigations on wildlife echinococcosis in sub-Saharan Africa. For obvious reasons, relevant numbers of wild animals are difficult to obtain for necropsy, so systematic surveys will largely depend on the analysis of faecal samples from carnivores. To achieve realistic prevalence estimates, detection methods need improvement in terms of sensitivity. Application of qPCR methods as recently developed are likely to provide a way forward (Maksimov et al., 2020; Knapp et al., 2023), although the diversity of *Echinococcus* spp., as found in this study, will be a challenge for routine application with large numbers of samples.

Ethical aspects

Research permits were issued for the work by the Ministry of Environment and Tourism (Permit No.: 1740/2012) as well as the National Commission on Research, Science and Technology (Authorization No.: AN202101126) in line with Namibian regulations.

Financial support

This study was funded by the Deutsche Forschungsgemeinschaft (DFG, German Research Foundation) - KE282-9/1, -12/1, RO3753-3/1, -9/1 - and conducted as part of the “Cystic Echinococcosis in sub-Saharan Africa Research Initiative (CESSARI)”.

Declaration of competing interest

The authors declare that they have no known competing financial interests or personal relationships that could have appeared to influence the work reported in this paper.

Acknowledgements

We thank the Namibian Ministry of Environment, Forestry and Tourism for the support by allowing access to the parks and material as well as making time and staff available. We further thank Dr. Philip Stander who provided lion, leopard, and brown hyena samples from the Kunene region.

References

- Addy, F., Wassermann, M., Kagendo, D., Ebi, D., Zeyhle, E., Elmahdi, I.E., Umhang, G., Casulli, A., Harandi, M.F., Aschenborn, O., Kern, P., Mackenstedt, U., Romig, T., 2017. Genetic differentiation of the G6/7 cluster of *Echinococcus canadensis* based on mitochondrial marker genes. *Int. J. Parasitol.* 47, 923–931. <https://doi.org/10.1016/j.ijpara.2017.06.003>.
- Alvarez Rojas, C.A., Romig, T., Lightowlers, M.W., 2014. *Echinococcus granulosus sensu lato* genotypes infecting humans – review of current knowledge. *Int. J. Parasitol.* 44, 9–18. <https://doi.org/10.1016/j.ijpara.2013.08.008>.
- Aschenborn, J., Schneider, C., Addy, F., Aschenborn, O., Kern, P., Romig, T., Deplazes, P., Wassermann, M., 2022. Cystic echinococcosis of ruminant livestock in Namibia. *Vet. Parasitol. Reg. Stud. Rep.* 31, 100727 <https://doi.org/10.1016/j.vprsr.2022.100727>.
- Basson, P.A., McCully, R.M., Kruger, S.P., Niekerk, J.W. van, Young, E., Vos, V. de, 1970. Parasitic and other diseases of the african buffalo in the Kruger national park. *Onderstepoort J. Vet. Res.* 37, 11–28.
- Boomker, J., Horak, I.G., Vos, V. de, 1989. Parasites of South African wildlife. IV. Helminths of kudu, *Tragelaphus strepsiceros*, in the Kruger national park. *Onderstepoort J. Vet. Res.* 56, 111–121.
- Boufana, B., Said, Y., Dhibi, M., Craig, P.S., Lahmar, S., 2015. *Echinococcus granulosus sensu stricto* (s.s.) from the critically endangered antelope *Addax nasomaculatus* in Tunisia. *Acta Trop.* 152, 112–115. <https://doi.org/10.1016/j.actatropica.2015.08.015>.
- Cardona, G.A., Carmena, D., 2013. A review of the global prevalence, molecular epidemiology and economics of cystic echinococcosis in production animals. *Vet. Parasitol.* 192, 10–32. <https://doi.org/10.1016/j.vetpar.2012.09.027>.
- Deplazes, P., Rinaldi, L., Alvarez Rojas, C.A., Torgerson, P.R., Harandi, M.F., Romig, T., Antolova, D., Schurer, J.M., Lahmar, S., Cringoli, G., Magambo, J., Thompson, R.C. A., Jenkins, E.J., 2017. Chapter six - global distribution of alveolar and cystic echinococcosis. *Adv. Parasitol.* 95, 315–493. <https://doi.org/10.1016/bs.apar.2016.11.001>.
- Graber, M., Thal, J., 1980. L'échinococcosse des artiodactyles sauvages de la République Centrafricaine: existence probable d'un cycle lion-phacochère. *Rev. Elev. Med. Vet. Pays Trop.* 33, 51–59. <https://doi.org/10.19182/remvt.8236>.

- Graber, M., Troncy, P., Tabo, R., 1969. L'échinococcose-hydatidose en Afrique centrale. I. Rev. élev. méd. vét. pays trop. 22, 55. <https://doi.org/10.19182/remvt.7663>.
- Halajian, A., Luus-Powell, W.J., Roux, F., Nakao, M., Sasaki, M., Lavikainen, A., 2017. *Echinococcus felidis* in hippopotamus, South Africa. Vet. Parasitol. 243, 24–28. <https://doi.org/10.1016/j.vetpar.2017.06.001>.
- Hüttner, M., Nakao, M., Wassermann, T., Siefert, L., Boomker, J.D.F., Dinkel, A., Sako, Y., Mackenstedt, U., Romig, T., Ito, A., 2008. Genetic characterization and phylogenetic position of *Echinococcus felidis* ortlepp, 1937 (cestoda: taeniidae) from the african lion. Int. J. Parasitol. 38, 861–868. <https://doi.org/10.1016/j.ijpara.2007.10.013>.
- Hüttner, M., Romig, T., 2009. *Echinococcus* species in African wildlife. Parasitology 136, 1089–1095. <https://doi.org/10.1017/S0031182009990461>.
- Hüttner, M., Siefert, L., Mackenstedt, U., Romig, T., 2009. A survey of *Echinococcus* species in wild carnivores and livestock in East Africa. Int. J. Parasitol. 39, 1269–1276. <https://doi.org/10.1016/j.ijpara.2009.02.015>.
- Jenkins, D.J., Macpherson, C.N.L., 2003. Transmission ecology of *Echinococcus* in wildlife in Australia and Africa. Parasitology 127, S63–S72. <https://doi.org/10.1017/S0031182003003871>.
- Kagendo, D., Magambo, J., Agola, E.L., Njenga, S.M., Zeyhle, E., Mulinge, E., Gitonga, P., Mbae, C., Muchiri, E., Wassermann, M., Kern, P., Romig, T., 2014. A survey for *Echinococcus* spp. of carnivores in six wildlife conservation areas in Kenya. Parasitol. Int. 63, 604–611. <https://doi.org/10.1016/j.parint.2014.04.001>.
- Knapp, J., Lallemand, S., Monnien, F., Felix, S., Courquet, S., Umhang, G., Millon, L., 2023. Real-time multiplex PCR for human echinococcosis and differential diagnosis. Parasite 30, 3. <https://doi.org/10.1051/parasite/2023003>.
- Krecek, R.C., Boomker, J., Penzhorn, B.L., Scheepers, L., 1990. Internal parasites of giraffes (*Giraffa camelopardalis angolensis*) from Etosha national park, Namibia. J. Wildl. Dis. 26, 395–397. <https://doi.org/10.7589/0090-3558-26.3.395>.
- Kumaratilake, L.M., Thompson, R.C.A., Eckert, J., 1986. *Echinococcus granulosus* of equine origin from different countries possess uniform morphological characteristics. Int. J. Parasitol. 16, 529–540. [https://doi.org/10.1016/0020-7519\(86\)90089-5](https://doi.org/10.1016/0020-7519(86)90089-5).
- Macpherson, C.N., Karstad, L., Stevenson, P., Arundel, J.H., 1983. Hydatid disease in the Turkana District of Kenya. III. The significance of wild animals in the transmission of *Echinococcus granulosus*, with particular reference to Turkana and Masailand in Kenya. Ann. Trop. Med. Parasitol. 77, 61–73.
- Maksimov, P., Bermann, H., Wassermann, M., Romig, T., Gottstein, B., Casulli, A., Contraths, F.J., 2020. Species detection within the *Echinococcus granulosus* sensu lato complex by novel probe-based real-time PCR. Pathogens 9, 791. <https://doi.org/10.3390/pathogens9100791>.
- Marchiori, E., Obber, F., Celva, R., Marver, F., Danesi, P., Maurizio, A., Cenni, L., Massolo, A., Citterio, C.V., Cassini, R., 2023. Comparing copromicroscopy to intestinal scraping to monitor red fox intestinal helminths with zoonotic and veterinary importance. Front. Vet. Sci. 9, 1085996. <https://doi.org/10.3389/fvets.2022.1085996>.
- Mathis, A., Deplazes, P., Eckert, J., 1996. An improved test system for PCR-based specific detection of *Echinococcus multilocularis* eggs. J. Helminthol. 70, 219–222.
- McCully, R.M., Niekerk, J.W. van, Kruger, S.P., 1967. Observations on the pathology of bilharziasis and other parasitic infestations of *Hippopotamus amphibius* Linnaeus, 1758, from the Kruger National Park. Onderstepoort J. Vet. Res. 34, 563–617.
- McCully, R.M., Kruger, S.P., Basson, P.A., Ebedis, H., Van Niekerk, J.W., 1969. Strongyloidosis : delafondiasis in the zebra. Onderstepoort J. Vet. Res. 36, 105.
- Melzheimer, J., Streif, S., Wasiolka, B., Fischer, M., Thalwitzer, S., Heinrich, S.K., Weigold, A., Hofer, H., Wachter, B., 2018. Queuing, takeovers, and becoming a fat cat: long-term data reveal two distinct male spatial tactics at different life-history stages in Namibian cheetahs. Ecosphere 9, e02308. <https://doi.org/10.1002/ecs2.2308>.
- Miamba, R.D., Afonso, S.M.S., Noormahomed, E.V., Pondja, A., Mukaratirwa, S., 2020. Echinococcosis in humans and animals in Southern Africa Development Community countries: a systematic review. Food Waterborne Parasitol 20, e00087. <https://doi.org/10.1016/j.fawpar.2020.e00087>.
- Mitchell, P., 2022. The horse in southern Africa. Oxford research encyclopedia of african history. <https://doi.org/10.1093/acrefore/9780190277734.013.850>.
- Mogoye, B.K., Menezes, C.N., Wong, M.L., Stacey, S., von Delft, D., Wahlers, K., Wassermann, M., Romig, T., Kern, P., Grobusch, M.P., Freaux, J., 2013. First insights into species and genotypes of *Echinococcus* in South Africa. Vet. Parasitol. 196, 427–432. <https://doi.org/10.1016/j.vetpar.2013.03.033>.
- Mulinge, E., Zeyhle, E., Mbae, C., Gitau, L., Kaburu, T., Magambo, J., Mackenstedt, U., Romig, T., Kern, P., Wassermann, M., 2023. Cystic echinococcosis in donkeys in eastern Africa. Parasitology. <https://doi.org/10.2017/S0031182023000173>, 150, 468–475.
- Naidoo, R., Chase, M.J., Beyteli, P., Preez, P.D., Landen, K., Stuart-Hill, G., Taylor, R., 2016. A newly discovered wildlife migration in Namibia and Botswana is the longest in Africa. Oryx 50, 138–146. <https://doi.org/10.1017/S0030605314000222>.
- Nakao, M., Sako, Y., Ito, A., 2003. Isolation of polymorphic microsatellite loci from the tapeworm *Echinococcus multilocularis*. Infect. Genet. Evol. 3, 159–163. [https://doi.org/10.1016/S1567-1348\(03\)00070-4](https://doi.org/10.1016/S1567-1348(03)00070-4).
- Nelson, G.S., Rausch, R.L., 1963. *Echinococcus* infections in man and animals in Kenya. Ann. Trop. Med. Parasitol. 57, 136–149. <https://doi.org/10.1080/00034983.1963.11686169>.
- Obwaller, A., Schneider, R., Walochnik, J., Gollackner, B., Deutz, A., Janitschke, K., Aspöck, H., Auer, H., 2004. *Echinococcus granulosus* strain differentiation based on sequence heterogeneity in mitochondrial genes of cytochrome c oxidase-1 and NADH dehydrogenase-1. Parasitology 128, 569–575. <https://doi.org/10.1017/S0031182004004871>.
- Romig, T., Deplazes, P., Jenkins, D., Giraudoux, P., Massolo, A., Craig, P.S., Wassermann, M., Takahashi, K., de la Rue, M., 2017. Chapter five - ecology and life cycle patterns of *Echinococcus* species. Adv. Parasitol. 95, 213–314. <https://doi.org/10.1016/bs.apar.2016.11.002>.
- Romig, T., Omer, R.A., Zeyhle, E., Hüttner, M., Dinkel, A., Siefert, L., Elmahdi, I.E., Magambo, J., Ocaido, M., Menezes, C.N., Ahmed, M.E., Mbae, C., Grobusch, M.P., Kern, P., 2011. Echinococcosis in sub-saharan Africa: emerging complexity. Vet. Parasitol. 181, 43–47. <https://doi.org/10.1016/j.vetpar.2011.04.022>.
- Rossouw, G.J., Knott-Craig, C.J., Erasmus, P.E., 1992. Cardiac echinococcosis: cyst removal in a beating heart. Ann. Thorac. Surg. 53, 328–329. [https://doi.org/10.1016/0003-4975\(92\)91343-8](https://doi.org/10.1016/0003-4975(92)91343-8).
- Schneider, C., 2020. Identität von *Echinococcus* spp. in domestizierten Tieren im nördlichen Namibia (Identity of *Echinococcus* spp. from domesticated animals in northern Namibia). MSc-thesis, University of Hohenheim, Stuttgart, Germany.
- Swart, H., Kotze, A., Olivier, P.A.S., Grobler, J.P., 2010. Microsatellite-based characterization of Southern African domestic pigs (*Sus scrofa domestica*). S. Afr. J. Anim. Sci. 40, 121–132. <https://doi.org/10.4314/sajas.v40i2.57280>.
- Verster, A., Collins, M., 1966. The incidence of hydatidosis in the Republic of South Africa. Onderstepoort J. Vet. Res. 33, 49–71.
- Verster, A.J.M., 1965. Review of *Echinococcus* species in South Africa. Onderstepoort J. Vet. Res. 32, 7–118.
- Wahlers, K., Menezes, C.N., Wong, M.L., Zeyhle, E., Ahmed, M.E., Ocaido, M., Stijnis, C., Romig, T., Kern, P., Grobusch, M.P., 2012. Cystic echinococcosis in sub-Saharan Africa. Lancet Infect. Dis. 12, 871–880. [https://doi.org/10.1016/S1473-3099\(12\)70155-X](https://doi.org/10.1016/S1473-3099(12)70155-X).
- Wassermann, M., Aschenborn, O., Aschenborn, J., Mackenstedt, U., Romig, T., 2015. A sylvatic lifecycle of *Echinococcus equinus* in the Etosha national park, Namibia. Int. J. Parasitol. Parasites Wildl. 4, 97–103. <https://doi.org/10.1016/j.ijppaw.2014.12.002>.
- Young, E., 1975a. Echinococcosis (hydatidosis) in wild animals of the Kruger national park. J. S. Afr. Vet. Assoc. 46, 285–286.
- Zaffarano, G.P., de Klerk-Lorist, L.-M., Junker, K., Mitchell, E., Bhoora, R.V., Poglajen, G., Govender, D., 2021. First report of cystic echinococcosis in rhinos: a fertile infection of *Echinococcus equinus* in a Southern white rhinoceros (*Ceratotherium simum simum*) of Kruger National Park, South Africa. Int. J. Parasitol. Parasites Wildl. 14, 260–266. <https://doi.org/10.1016/j.ijppaw.2021.02.007>.